



What is Your Radiologic Diagnosis?

Radyolojik Tanınız Nedir?

Gözde Özer (ID), Adalet Elçin Yıldız (ID)

Department of Radiology, Hacettepe University Faculty of Medicine, Ankara, Türkiye

Cite this article as: Özer G, Yıldız AE. What is your radiologic diagnosis? J Pediatr Inf 2022;16(4):e298-e300.

An eight-year-old girl, with diagnosis of hereditary sensory and autonomic neuropathy type 2 was admitted to our hospital with the complaint of a wound on the right big toe. Her history revealed that she had had debridement in another center three years prior with the diagnosis of osteomyelitis with an abscess on the left big toe. The patient's family realized that the patient did not feel pain when she hit her foot. Sensory polyneuropathy was detected during the patient's electromyography evaluation, and genetic test confirmed the diagnosis of hereditary sensory autonomic neuropathy type 2. During her admission to our hospital, a 2 x 2 cm, erythematous and edematous ulcerated lesion with drainage was discovered on her right big toe. Body temperature (36.7°C) and other vital signs were normal. Laboratory tests revealed an increase in C-reactive protein level and erythrocyte sedimentation rate (CRP= 8.6 mg/dL, ESR= 83 mm/hour). The blood culture taken after hospitalization with a prediagnosis of osteomyelitis was negative. Methicillin-resistant *Staphylococcus aureus* and *Pseudomonas aeruginosa* were isolated in the wound culture taken from the ulcerated lesion. On the right foot radiographs, soft tissue swelling, which was more prominent around the first metatarsophalangeal joint, was accompanied by an increase in joint distance and bone fragments (Figure 1). Contrast-enhanced magnetic resonance imaging (MRI) of the right foot revealed a sinus tract in the vicinity of the medial plantar of the first metatarsophalangeal joint, osteitis in the first proximal phalanx and metatarsal, and active inflammato-

ry arthritis in the metatarsophalangeal joint (Figure 2). On the ankle radiography and MRI, destruction of the talus and calcaneus adjacent to the subtalar joint, bone marrow edema in these bones, and effusion in the subtalar-tibiotalar joint were observed (Figure 3). What is your diagnosis based on the patient's radiography and MRI findings?

Diagnosis: Neuropathic arthropathy with superimposed osteomyelitis

Brief Discussion

Today, neuropathic arthropathy is most commonly seen as a complication of neuropathy secondary to diabetes mellitus in adult patients (1). Although it is rare in children compared to adults, its association with hereditary sensory and autonomic neuropathy, syringomyelia, and spina bifida has been reported (2-4). The primary disease that causes neuropathy in children may first manifest with arthritis symptoms (3). Therefore, it is very important to keep neuropathic arthropathy as a rare pathology in mind in the differential diagnosis of patients presenting with arthritis and to evaluate the neurological examination and imaging findings together.

Two basic mechanisms have been suggested in the pathogenesis of neuropathic arthropathy (5). The neurotraumatic mechanism is defined as repetitive traumas resulting in joint destruction due to sensory and motor neural dysfunction. The neurovascular mechanism is the loss of sympathetic neural tone resulting in vasodilation and increased osteoclastic activ-

Correspondence Address/Yazışma Adresi

Gözde Özer

Hacettepe Üniversitesi Tıp Fakültesi,
Radyoloji Anabilim Dalı,
Pediatrik Radyoloji Bilim Dalı
Ankara-Türkiye

E-mail: gozdetufan@gmail.com

Received: 02.11.2022

Accepted: 25.11.2022

Available Online Date: 14.12.2022

©Copyright 2022 by Pediatric Infectious Diseases and Immunization Society.
Available online at www.cocukenfeksiyon.org

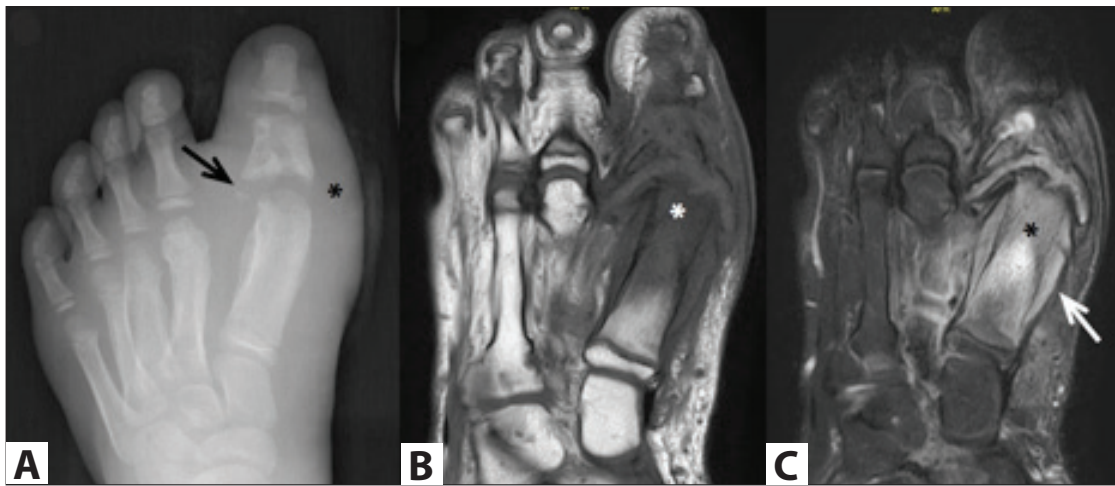


Figure 1. Anteroposterior radiograph of the right foot (A) enlargement of the first metatarsophalangeal and interphalangeal joints, irregularity, and fragmentation of the articular surfaces (black arrow), solid periosteal reaction and sclerosis in the first to third metatarsals, sclerosis in the proximal phalanx with lytic areas and soft tissue swelling around the joint (asterisk). On long axis T1-weighted pre-contrast (B) and fat-suppressed T2-weighted (C) images, bone marrow intensity changes (asterixes) consistent with osteomyelitis around the first metatarsophalangeal joint and periosteal reaction surrounding the first metatarsal with destruction on the joint surfaces (white arrow) are observed.

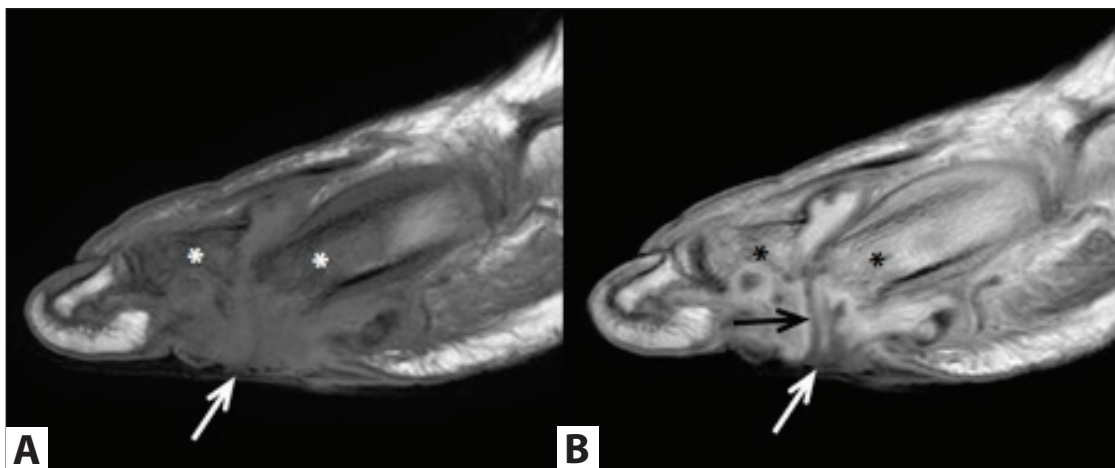

Figure 2. Skin ulcer (white arrows) on the plantar side of the first metatarsophalangeal joint on pre (A) and postcontrast (B) T1-weighted images in the sagittal plane, signal intensity changes consistent with osteomyelitis in the first metatarsal and proximal phalanx, and contrast enhancement (asterixes) and sinus tract extending into the joint space (black arrow) are observed.

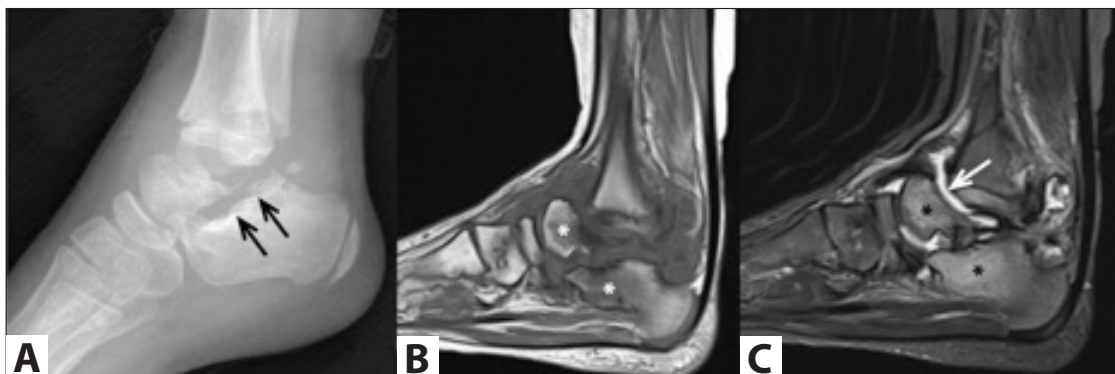


Figure 3. In the lateral ankle radiograph (A), bony destruction (black arrows) of talus and calcaneus and millimetric bone fragments are consistent with neuropathic arthropathy. On sagittal pre-contrast T1-weighted (B) and sagittal fat-suppressed T2-weighted (C) images, joint effusion (white arrow) accompanies bone marrow edema (asterisks) consistent with osteitis in the talus and calcaneus..

ity due to hyperemia causing neuropathic joint changes. This pathophysiological process is summarized as the “6D” findings of neuropathic arthropathy. In the acute phase, joint swelling (*distention*) with increased or normal bone density (*density*) is seen on the radiograph, followed by subchondral bone destruction (*destruction*) and intra-articular debris (*debris*). In the late period, *dislocation* develop due to joint *deformities* and ligament laxity as a result of progressive bone destruction (6).

In the acute phase of neuropathic arthropathy, mild swelling, redness, and warmth are seen in the affected joint, while swelling and joint deformities are the most common findings in the chronic phase. Although it is ideal to diagnose patients at an early stage, nonspecific findings in this period make the diagnosis difficult. Diagnosis is mostly made by typical findings on radiographs and progressive changes on follow-up radiographs (6).

Radiographically, neuropathic arthropathy is classified as hypertrophic, atrophic, and mixed type (5). The hypertrophic type is the typical form characterized by joint destruction and fragmentation, sclerosis of bones, and osteophytes. The atrophic type is mostly seen in non-weight-bearing areas and is characterized by bone resorption. In the mixed type, both joint destruction and fragmentation and bone resorption are seen. Persistent joint effusion is typically seen in all three types (5). In the early phase of neuropathic arthropathy, radiographs are mostly normal. MRI is the best imaging method to confirm the diagnosis during this period. The most common findings in early disease on MRI are soft tissue and bone marrow edema, joint effusion, and subchondral microfractures (7). In the late stage, joint destruction and dislocation are the most common findings. In addition, subchondral cysts, intra-articular fragments, and debris accompanying the effusion are also frequently detected (7).

Osteomyelitis is the main diagnostic challenge in the differential diagnosis of neuropathic arthropathy in the acute and late stages. Neuropathic arthropathy mimics infection with clinical findings such as swollen and red foot, and imaging findings such as bone marrow edema, joint effusion, and periarticular soft tissue enhancement. In addition, findings of chronic neuropathic arthropathy on MRI make it difficult to detect accompanying osteomyelitis. MRI demonstrates high sensitivity and specificity in the diagnosis of osteomyelitis (8). However, chronic neuropathic arthropathy findings such as joint effusion, subluxation, fragmentation, and joint destruction are seen with similar frequency in patients with or without concomitant infection (9). Some imaging findings have been described that may help diagnose osteomyelitis accompanying neuropathic arthropathy. The prominence of bone marrow edema adjacent to the joint is an expected finding for neuropathic arthropathy, while complete loss of normal bone marrow intensity in the affected

bone suggests infection (8,9). Intra-articular loose bodies and subchondral cysts are less common in the presence of infection, and the disappearance of subchondral cysts on follow-up should raise suspicion of infection. (7,9). Again, in the presence of infection, periarticular collections are detected more frequently (9). In addition, it has been reported that replacement of fat signal intensity in soft tissue, soft tissue enhancement, and skin ulcers can be seen in patients without infection. Yet, in the presence of all these imaging findings, the possibility of osteomyelitis accompanying neuropathic arthropathy should be noted. However, microbiological sampling is the gold standard method for the definitive diagnosis of infection (9).

In our case, imaging findings suggested osteomyelitis on the basis of neuropathic arthropathy. Joint debridement and bone sampling were performed by orthopedic surgeons. Methicillin-resistant *Staphylococcus aureus* and *Pseudomonas aeruginosa* were isolated in these samples, as in the wound culture. In addition to debridement, the patient's symptoms and acute phase reactants regressed after ampicillin+sulbactam and teicoplanin treatment.

References

1. Gazis A, Pound N, Macfarlane R, Treece K, Game F, Jeffcoate W. Mortality in patients with diabetic neuropathic osteoarthropathy (Charcot foot). *Diabet Med* 2004;21(11):1243-6. <https://doi.org/10.1111/j.1464-5491.2004.01215.x>
2. Feldman DS, Ruchelsman DE, Spencer DB, Straight JJ, Schweitzer ME, Axelrod FB. Peripheral arthropathy in hereditary sensory and autonomic neuropathy types III and IV. *J Pediatr Orthop* 2009;29(1):91-7. <https://doi.org/10.1097/BPO.0b013e31818f9cc4>
3. Zei MG, Meyers AB, Vora S. Pediatric neuropathic arthropathy initially masquerading as inflammatory arthritis. *J Clin Rheumatol* 2014;20(7):383-5. <https://doi.org/10.1097/RHU.0000000000000122>
4. Yalcin S, Kocaoglu B, Berker N, Erol B. Conservative treatment of Charcot arthropathy in a series of spina bifida patients: the experience of one center and review of the literature. *J Pediatr Orthop B* 2007;16(5):373-9. <https://doi.org/10.1097/01.bpb.0000218029.81395.95>
5. Jones EA, Manaster BJ, May DA, Disler DG. Neuropathic osteoarthropathy: diagnostic dilemmas and differential diagnosis. *Radiographics* 2000;20:279-93. https://doi.org/10.1148/radiographics.20.suppl_1.g00oc22s279
6. Chan RLS, Chan CH, Chan HF, Pan NY. The many facets of neuropathic arthropathy. *BJR Open* 2019;29(1):20180039. <https://doi.org/10.1259/bjro.20180039>
7. Roskopf AB, Loupatatzis C, Pfirrmann CWA, Böni T, Berli MC. The Charcot foot: A pictorial review. *Insights Imaging* 2019;5;10(1):77. <https://doi.org/10.1186/s13244-019-0768-9>
8. Johnson PW, Collins MS, Wenger DE. Diagnostic utility of T1-weighted MRI characteristics in evaluation of osteomyelitis of the foot. *AJR Am J Roentgenol* 2009;192(1):96-100. <https://doi.org/10.2214/AJR.08.1376>
9. Ahmadi ME, Morrison WB, Carrino JA, Schweitzer ME, Raikin SM, Lerdemann HP. Neuropathic arthropathy of the foot with and without superimposed osteomyelitis: MR imaging characteristics. *Radiology* 2006;238(2):622-31. <https://doi.org/10.1148/radiol.2382041393>